



Original Research

Imaging-derived biomarkers in Asthma: Current status and future perspectives

Esther Pompe^a, Anastasia KAL. Kwee^a, Vickram Tejwani^b, Trishul Siddharthan^c, Firdaus AA. Mohamed Hoessein^{a,*}

^a Department of Radiology, University Medical Center Utrecht, Utrecht, the Netherlands

^b Respiratory Institute, Cleveland Clinic (VT), USA

^c Division of Pulmonary, Critical Care and Sleep Medicine, University of Miami (TS), USA



ARTICLE INFO

Keywords:

Asthma
Artificial intelligence (AI)
Imaging
Quantitative

ABSTRACT

Asthma is a common disorder affecting around 315 million individuals worldwide. The heterogeneity of asthma is becoming increasingly important in the era of personalized treatment and response assessment. Several radiological imaging modalities are available in asthma including chest x-ray, computed tomography (CT) and magnetic resonance imaging (MRI) scanning. In addition to qualitative imaging, quantitative imaging could play an important role in asthma imaging to identify phenotypes with distinct disease course and response to therapy, including biologics. MRI in asthma is mainly performed in research settings given cost, technical challenges, and there is a need for standardization. Imaging analysis applications of artificial intelligence (AI) to subclassify asthma using image analysis have demonstrated initial feasibility, though additional work is necessary to inform the role of AI in clinical practice.

1. Introduction

Asthma is a common disorder affecting around 315 million individuals worldwide [1]. The heterogeneity of asthma is becoming increasingly recognized and highlights a need for personalized medicine and the development of targeted therapeutic approaches. However, better biomarkers are needed to predict and monitor disease progression and treatment response. Imaging is not included in the routine management of asthma, but could become increasingly important in asthma care in the future, as the disease's hallmarks (airway narrowing and widening, mucus hypersecretion) can all be captured at once.

Several radiological modalities are available for imaging asthma ranging from a simple chest x-ray to chest computed tomography (CT), magnetic resonance imaging (MRI), and even sometimes nuclear imaging. The majority of asthma patients will not undergo imaging as current guidelines mainly rely on clinical symptoms and lung function testing. The role of chest x-ray is limited to the acute setting of acute exacerbations to rule out barotrauma or an infectious process. A chest CT might be indicated in patients with severe and/or uncontrollable asthma and ideally includes inspiration and expiration CT, guided by an

experienced technician. Non-ionizing imaging is preferred to limit radiation exposure, but the role of these imaging modalities (e.g. MRI) is limited, because of technical challenges, costs, availability, and lack of standardization. In addition, it requires long breath holds, and sometimes sedation in children [2].

Imaging biomarkers could be useful for defining specific phenotypes and for prediction and/or assessment of therapy response similar to the paradigm of T2-targeted biologics for those with the T2-high asthma phenotype. As imaging biomarkers are non-invasive, they could play an important role both in research and in clinical practice. Additionally, advances in radiological techniques and imaging biomarkers, augment the role of imaging in respiratory disease. In this review we will discuss recent advances and future developments in the imaging of asthma. We will focus on the role of CT and MRI as non-invasive biomarkers in asthma as these are most promising and have shown the most advances in recent years.

2. Computed tomography and quantitative imaging

In the acute setting, a CT is traditionally performed when the findings of the chest x-ray are not clear or there is a high suspicion of a

* Corresponding author.

E-mail addresses: esther.pompe@gmail.com (E. Pompe), A.K.A.L.Kwee-2@umcutrecht.nl (A.KAL. Kwee), tejwanv@ccf.org (V. Tejwani), tsiddhar@miami.edu (T. Siddharthan), fmohamedhoseein@gmail.com (F.AA. Mohamed Hoessein).

<https://doi.org/10.1016/j.rmed.2023.107130>

Received 10 October 2022; Received in revised form 20 January 2023; Accepted 21 January 2023

Available online 23 January 2023

0954-6111/© 2023 The Authors. Published by Elsevier Ltd. This is an open access article under the CC BY license (<http://creativecommons.org/licenses/by/4.0/>).

Abbreviations

AI	artificial intelligence
CT	computed tomography
E/I-ratio _{MLD}	Expiratory to inspiratory ratio of mean lung density
FRC	forced residual capacity
³ He	hyperpolarized helium-3
HU	Hounsfield unit
¹ H	Oxygen-enhanced hydrogen-1
LAA	Low attenuation area
MRI	magnetic resonance imaging
Pi10	the square root of airway wall area of a hypothetical airway with 10 mm inner perimeter
PRM	parametric response mapping
QIBA	quantitative Imaging Biomarkers Alliance
SA/V	airway luminal surface area to volume
WA	wall area
WT	wall thickness

disease in addition to an asthma exacerbation. Pneumothorax, pneumomediastinum and pulmonary infections can be readily diagnosed on chest CT. Beyond this, CT is used for assessing large and small airway disease. Bronchial wall thickening, bronchiectasis and mucus plugging are markers for large airway disease in asthma, but can also reflect underlying infectious processes such as allergic bronchopulmonary aspergillosis [3]. Small airway disease is more difficult to diagnose on an inspiration CT scan only, hence low attenuation areas (LAA) on expiratory CT are used as a surrogate of small airway obstruction. The term air trapping in this setting is incorrect, as this suggests a dynamic process. Furthermore, LAA can be a result of hypoperfusion.

Quantitative imaging is an increasingly used, non-invasive tool that can provide detailed structural and functional information of the airways. Quantitative imaging is defined as “the extraction of quantifiable features from medical images for the assessment of normal or the severity, degree of change, or status of a disease, injury, or chronic condition relative to normal” [4]. It can be a useful addition to lung function testing and can assist clinicians in diagnosing, monitoring or phenotyping a range of chronic lung diseases and has been similarly applied to chronic obstructive pulmonary disease (COPD). Most research on quantitative imaging is performed using inspiratory chest CT and mainly includes characteristics of the larger airways (e.g. airway wall thickness, wall area, lumen area) [5]. In some datasets, both inspiratory and expiratory chest CT are available, with which LAA, as a surrogate marker for small airway disease, can be assessed [6]. For asthma, there are several relevant types of quantitative biomarkers, which will be discussed below.

2.1. Large airway disease

The large airways can be evaluated with orthogonal measurements along the airways, enabled by three-dimensional segmentation methods, and may have a role in the noninvasive measurement of airway remodeling. Several measurements can be depicted, such as lumen area, wall thickness (WT) and wall area (WA), mostly adjusted for airway size (WT% and WA%) [7]. WT% and WA% have been associated with airway epithelial thickness, disease severity, and bronchodilator responsiveness [8], and proximal airway thickness may distinctly contribute to impaired lung function in asthma [9]. However, these measurements are somewhat limited, as accurate matching of measurements rely on adequate labeling of the airway tree. Nevertheless, measurements such as luminal area and WA% can still provide disease insight when averaged over airway generations and regions. The square root of airway

wall area of a hypothetical airway with 10 mm inner perimeter (Pi10) is a measurement that may be interpreted as an index measurement for airway wall thickness, as Pi10 is based on luminal perimeters and airway wall area measurements collected at every 1 mm throughout the entire airway tree. Pi10 is insensitive to the number of airways segmented and therefore seems to be a more robust airway metric. Although Pi10 has been widely studied in COPD cohorts, Pi10 results in individuals with asthma are more scarce. A study of Krings et al. found that greater Pi10 was associated with future lung function decline [10].

The aforementioned metrics reflect components of large airway disease (airway wall thickening), whereas loss of airways (total airway count) plays an important role in asthma as well [11]. For this reason, the airway luminal surface area to volume (SA/V) has been introduced as a marker of dysanapsis or mismatch between airway and lung size. Progressive airway narrowing can result in an increase in SA/V, and predominant airway loss will result in a decrease in SA/V. This metric, however, has only been evaluated in patients with COPD [12]. Finally, endobronchial obstruction caused by mucus plugging can be evaluated using CT analysis, and has been found to be correlated with severity of obstruction [13,14]. Unfortunately, mucus plugging scores are time consuming to assess visually and fully automated analysis techniques are currently being validated.

Another prevalent finding in individuals with asthma is bronchiectasis, which on CT are defined as abnormally widened airways with a lack of tapering and/or visibility of the airway in the periphery of the lung [15]. Bronchiectasis has been identified in up to 47% of patients with severe asthma and seems to be a phenotypic feature of eosinophilic asthma [16]. Fully automated detection of bronchiectasis is much needed, as the diagnosis is sensitive to inter-observer variability [17]. By calculating the ratio between an airway and an accompanying artery, objective criteria can be developed to diagnose bronchiectasis, as has been done in cystic fibrosis [18]. At present, it is possible to fully automatically measure the airway-artery ratio of both central and peripheral airways, as presented in a conference abstract, where mainly peripheral airway-artery ratios seem to contribute to airway obstruction in COPD patients [19]. It would be interesting to assess how this airway-artery ratio behaves in early and more severe stages of asthma. Additionally, to allow for comparison between individuals and disease diagnosis, reference values for normal airway and artery dimensions need to be developed.

2.2. Small airway disease

The small airways, defined as airways with an internal diameter of <2 mm, play an important part in the clinical presentation of asthma due to inflammation, narrowing and remodeling of the airways [20,21]. The small airways are difficult to visualize due to the resolution of CT scans, but LAA on expiratory CT, as a surrogate for small airways disease, can be assessed. LAA is a biomarker defined on CT as low attenuation areas due to the retention of excess gas in (part of) the lungs during any stage of expiration, due to airway obstruction or local abnormalities in pulmonary compliance [22].

Several measures can be used to quantify LAA on CT. A commonly used measure is the expiratory mean lung density divided by the inspiratory mean lung density, presented as a ratio: E/I-ratio_{MLD}. This ratio was found to be the most accurate marker in the detection of LAA in a cohort of lung cancer screening subjects [16]. Another method is to measure the percentage of voxels with an attenuation below a certain threshold in Hounsfield Units (HU) on expiratory CT scan.

Previous literature has shown associations between CT quantified LAA biomarkers and clinical outcome parameters in patients with asthma. Busacker et al. (2009) studied patients from the Severe Asthma Research Program (SARP) and found that LAA (defined as >9.66% of lung tissue below -850 HU) in asthma patients was associated with a decreased lung function, longer asthma duration, and patients were more likely to have a medical history of pneumonia and atopy [23]. A

study from Gupta et al. (2014) hypothesized that CT-quantified proximal airway remodeling and LAA (measured with E/I-ratio_{MLD}) could identify different asthma phenotypes. Three asthma clusters were identified, of which LAA was present in all three [24]. More recently, Krings et al. (2021) analyzed 205 CT scans from the SARP-3 cohort and concluded that an increased amount of LAA (defined as percentage of voxels -856 HU at functional residual capacity [FRC]) and hyperinflation were associated with more frequent future exacerbations [25].

While the abovementioned biomarkers have shown associations with clinical outcome parameters of asthma, they are not able to distinguish LAA as a result of small airways disease from LAA as a result of emphysema on standard CT. This is important in asthma patients where emphysema is present as well. To make this distinction, co-registration of inspiratory and expiratory CT is needed, with which emphysematous LAA can be differentiated from non-emphysematous LAA [26]. An example of this so-called parametric response map (PRM) is shown in Fig. 1. LAA values based on PRM are associated with pulmonary function parameters and clinical traits in COPD [27]. In asthma, Bell et al. have used PRM to demonstrate that reduced ventilation in inferior regions of the lung are associated with physiologic measurements of ventilation heterogeneity. This may have implications for inhalation therapies in asthma patients [28].

Recently, results of the ATLANTIS study have been published, a large prospective cohort study assessing small airways dysfunction in asthma. They did not find a correlation between CT-biomarkers of LAA and asthma control, exacerbations, or quality of life. Notably, they did only rely on ‘conventional’ CT density measurements and CT-derived lung volumes [29].

As opposed to areas of low attenuation, lung density can be increased as well, and may present as ground glass, consolidation or linear densities (septal thickening). Evaluation of these structural parenchymal abnormalities has been performed visually in 20 atopic subjects following an allergen challenge, which resulted in consolidations and septal thickening, in 55% and 35% of subjects, respectively [30]. In addition, in children with asthma, lung abnormalities (mainly linear densities and airway wall thickening) were identified on CT in those with an inflammatory response on bronchoscopic alveolar lavage fluid [31]. These studies demonstrate the potential of imaging as a noninvasive clinical tool for characterization of asthma phenotypes, which may be translated to the development of new therapies. The automated assessment of ground glass and consolidation using artificial intelligence has been accelerated because of the COVID-19 pandemic and could be translated to other lung diseases, such as asthma [32].

2.3. Vasculature

An area that has not been researched much in asthma is vasculature. Asthma has been thought of as a disease of the airways, but vascular inflammation and remodeling may play a role as well. We know that in COPD, a smaller relative volume of the peripheral pulmonary

vasculature (vascular pruning), measured using CT, is associated with disease severity and cardiac dysfunction [33]. Indeed, by using quantitative CT analysis in the SARP-3 cohort, severe asthma was found to be associated with more pruning of the pulmonary vasculature as compared to mild-moderate asthma or healthy control subjects. In addition, vascular pruning was associated with worse lung function, eosinophilia, and asthma exacerbation. Unfortunately, these findings have not been replicated in other cohorts and no pathologic correlates have been affirmed. Measurements were based on the combined volumes of the pulmonary arteries and veins, and therefore artery-vein segmentation has been developed [34,35]. New developments even seem to make it possible to depict both arteries and veins from non-contrast CT scans [36]. The attention of this important work tends to be aimed at COPD primarily but may become important in other chronic lung diseases as well. Also in asthma, the focus may shift from ‘pure’ airway research to the vascular component of airway remodeling, where both small and larger arteries could be affected [37].

3. MRI

Lung MRI is considered to be challenging, because of the low proton density of the lung, fast signal decay, and respiratory artifacts, but it might be a radiation-free alternative to CT. Up until now, MRI in asthma is mainly used in a research setting. The spatial resolution of MRI is less than that of CT, but can provide dynamic information. Low intensity regions on static proton MRI at residual volume can represent trapped air and/or hypoperfusion, but by usage of ventilation gasses, regional ventilation defects can be detected dynamically. Xenon and hyperpolarized helium-3 (^3He) are the two gasses mostly used. Patients with severe asthma show ventilation defects at MRI, and this correlates with LAA on CT [38–41]. The extent of ventilation defects at MRI is associated with asthma exacerbations and other clinical markers of asthma severity [42]. Ventilation imaging therefore appears to be clinically relevant in characterizing asthma and could be complementary in the evaluation of difficult to manage asthma in a clinical setting [43]. MRI with ^3He has been evaluated as a biomarker for assessing treatment response and a direct effect of bronchodilator inhalation has been observed in a specific group of severe asthma patients. This therapeutic effect was less in patients with sputum eosinophilia. Also, one study showed that the extent of ventilation defects decreased after bronchial thermoplasty [44] and subsequently there have been efforts to guide the location of bronchial thermoplasty using MRI imaging [45]. Additionally, ^3He MRI has shown to predict post-bronchodilator reversibility over time in patients with mild-to-moderate asthma, whereas no changes in lung function, medication, or exacerbations were observed [46].

Xenon and ^3He are quite expensive, require specific expertise and equipment and are laborious, which hampers the use at a broad scale. Oxygen-enhanced hydrogen 1 (^1H) MR imaging can provide ventilation maps as well, by measuring differences in ^1H signal at different lung

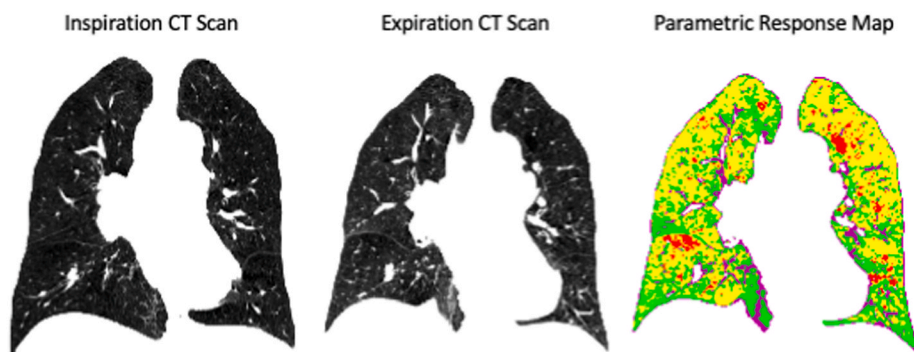


Fig. 1. Parametric Response Map (PRM) of a male asthma patient. He is on medium dose inhalation corticosteroids and long-acting bronchodilator inhalers. No exacerbations and no poor control was noted. FEV₁: 1.03L (53% FEV₁ percentage of predicted, FEV₁%). The percentage of functional small airways disease (fSAD) was 42%, represented in yellow. Emphysematous lung is represented in red (3%). Normal parenchyma is represented in green (34%). (For interpretation of the references to colour in this figure legend, the reader is referred to the Web version of this article.)

volumes, while the patient breathes pure oxygen and room air [47]. Although slightly less sensitive to changes in ventilation maps after treatment with salbutamol and methacholine, ^1H MR imaging might be considered in the evaluation of asthma patients in centers without inhaled-gas MRI [46,48]. Another advantage is that it is much less expensive than Xenon and ^3He , and that structural information can be acquired by this technique as well.

MRI can be used to evaluate perfusion, but most sequences require the administration of contrast. A contrast-free alternative to assess both ventilation and perfusion, is called phase resolved functional lung (PREFUL) MRI, which is based on Fourier decomposition methods [49]. A major drawback of this and afore mentioned MRI techniques, is that most sequences do not allow for 3D reconstructions, as opposed to CT.

Other challenges in MRI include the inherently slower acquisition compared with CT, which makes CT advantageous in younger children and other patients who are unable to maintain a breath hold. Breath hold maneuvers can be up to 20 s, which may not be feasible for patients with more severe asthma. Yet, MRI techniques are continually improving and successful free-breathing image acquisition has been performed in neonates with bronchopulmonary dysplasia [50]. The development of ultrashort echo time MRI sequences, where signal-to-noise ratio is improved due to the reduced susceptibility artifacts, provides structural information comparable to CT. Even zero echo time sequences have been introduced recently, which seem to be superior in capturing lung parenchymal signals [51].

4. Pitfalls, future perspectives and conclusion

Bronchoconstriction in asthmatic airways is widespread, affects small and large airways, and is unstable. These pathological processes can be evaluated using imaging, where CT can depict airway wall thickening and LAA, and MRI can be used to perform more detailed functional imaging, as well as directly evaluate treatment effect. Although radiographic phenotyping offers the promise for personalized therapeutic approaches, there are a number of limitations to adoption in clinical practice.

4.1. Reproducibility

A report by a radiologist currently does not contain any objective quantitative information on airway and arterial dimensions, or LAA, whereas adding computer based quantitative analysis data to the report is crucial. Unfortunately, introducing automated analysis techniques into daily clinical practice remains challenging. Quantitative imaging requires external post-processing software, which is costly. Also, advances in processing technology are occurring at a rapid pace and it can be difficult to choose which software is best. For this reason, quantitative imaging is mainly performed in large centers with large radiology departments and specialized imaging post-processing labs. An alternative would be to send the clinical images to a secured cloud where imaging post-processing companies can perform quantitative analyses and send the results back to the hospital system. For this purpose, imaging protocols must be standardized, as proposed by a recent position paper for protocols on hyperpolarized MRI studies [52]. Another important reason to standardize scanning protocols is the influence of inspiration and expiration level on the proposed imaging measurements. Standardization of volume level during inspiration is important for the detection of bronchiectasis and airway wall thickening, as these are highly dependent on lung volume [53–55]. In addition, low attenuation regions (CT) or low intensity regions (MRI) can be more sensitively assessed when the expiration scan is acquired near residual volume. Indeed, it has been shown that spirometrically gated CT or MRI in combination with a well-trained lung function technician can achieve an optimal result [56].

With standardization, imaging data becomes more generalizable, enabling international collaborations, large clinical and translational

imaging studies to be established, which can finally lead to personalized patient care. In addition, quantitative analyses using artificial intelligence (AI), and in particular deep learning, could ultimately be quicker, superior, and less costly.

4.2. Artificial Intelligence (AI)

AI is incorporated more and more in clinical research and daily practice. When coupled with a large amount of well characterized datasets, it yields models that can facilitate better patient care and research. Especially in chronic and prevalent diseases such as asthma, AI could become important in daily patient care [57]. It is, however, important to note that AI is not fully developed when it comes to quantitative imaging tasks. This has to do with several issues, such as specialized hardware/software/PACS systems, bias in training sets, paucity of high quality annotated data and research, and ethical issues regarding responsibility when classified incorrectly. In imaging asthma, AI could contribute twofold: it can improve the imaging technique and amplify image quality and imaging modalities such as CT and MRI, and can be analyzed by machine learning algorithms, generating biomarkers. Indeed, diagnostic imaging is the most widely employed data source in healthcare-oriented applications of AI [58]. In asthma, further work needs to be done in combining imaging data with clinical and genomic data in order to identify asthma phenotypes, which are perhaps more susceptible to specific treatment. In addition, imaging should be included in AI-driven asthma management decision trees.

4.3. Disease modifying effects of biologics

There is increasing evidence that biologic therapies targeting type-2 immunity have disease modifying effects, including on small airway remodeling [59]. It is therefore plausible that imaging outcomes may serve as more immediate assessments of an individual's response to a biologic medication, as opposed to longitudinal outcomes (e.g. corticosteroid use, hospitalization). Recent studies have identified the percentage of ventilation defects on ^{129}Xe MRI [60] as a sensitive biomarker of asthma airway dysfunction after administration of a single biologic medication. Ongoing studies are assessing biologic medications, such as tezepelumab (NCT05280418) and benralizumab (NCT03976310), with imaging outcomes as well as specific sub-phenotypes of asthma (e.g. luminal mucous occlusion, airway remodeling). In addition, there is an evolving framework for "remission" in asthma [61], based on outcomes that are primarily assessed over a 12-month duration. It is plausible that imaging may provide a more immediate assessment of disease status and allow for quicker adjustment of medications if imaging-derived biomarkers suggest an individual may not be in remission. The role of imaging may therefore be most valuable in those that have severe asthma.

In conclusion, quantitative imaging has been used in COPD research widely, as well as in other lung diseases such as bronchiectasis, cystic fibrosis, and bronchopulmonary dysplasia, but relatively little in asthma. As learned from COPD research, imaging may initially raise more questions than answers, but finally will lead to better characterization of the disease. Better characterization or phenotyping of asthma will lead towards new treatment development, treatment strategies, and preventative care.

Funding

We did not receive any specific grants from funding agencies in the public, commercial, or not-for-profit sectors regarding this article.

CRediT authorship contribution statement

Esther Pompe: Writing – original draft, Writing – review & editing.
Anastasia KAL. Kwee: Writing – original draft, Writing – review &

editing. **Vickram Tejwani:** Visualization, Writing – review and editing. **Trishul Siddharthan:** Visualization, Writing – review and editing. **Firdaus AA. Mohamed Hoesein:** Visualization, Writing – original draft, Supervision.

Declaration of competing interest

No conflicts of interest.

Acknowledgements

We would like to thank Prof. C.J. Galbán and Dr. Lugogo for their contribution by providing the figure in this manuscript.

References

- [1] T. To, S. Stanojevic, G. Moores, A.S. Gershon, E.D. Bateman, A.A. Cruz, et al., Global asthma prevalence in adults: findings from the cross-sectional World health survey, *BMC Publ. Health* 12 (2012) 204.
- [2] M.C. Liszewski, P. Ciet, A.J. Winant, E.Y. Lee, Lung and large airway imaging: magnetic resonance imaging versus computed tomography, *Pediatr. Radiol.* 52 (10) (2022 Sep) 1814–1825.
- [3] E. Polverino, K. Dimakou, J. Hurst, M.-A. Martinez-Garcia, M. Miravittles, P. Paggiaro, et al., The overlap between bronchiectasis and chronic airway diseases: state of the art and future directions, *Eur. Respir. J.* 52 (3) (2018), 1800328.
- [4] Radiological Society of North America [Accessed on September 12, Quantitative imaging biomarkers alliance, Available at: <http://www.rsna.org/QIBA.aspx>, 2022.
- [5] A. Niimi, H. Matsumoto, R. Amitani, Y. Nakano, M. Mishima, M. Minakuchi, et al., Airway wall thickness in asthma assessed by computed tomography. Relation to clinical indices, *AJRCCM* 162 (4 Pt 1) (2000) 1518–1523.
- [6] O.M. Mets, P. Zanen, J.W. Lammers, I. Isgum, H.A. Gietema, B. van Ginneken, et al., Early identification of small airways disease on lung cancer screening CT: comparison of current air trapping measures, *Lung* 190 (6) (2012) 629–633.
- [7] Y. Nakano, J.C. Wong, P.A. de Jong, L. Buzatu, T. Nagao, H.O. Coxson, et al., The prediction of small airway dimensions using computed tomography, *Am. J. Respir. Crit. Care Med.* 171 (2005) 142–146.
- [8] R.S. Aysola, E.A. Hoffman, D. Gierada, S. Wenzel, J. Cook-Granroth, J. Tarsi, et al., Airway remodeling measured by multidetector CT is increased in severe asthma and correlates with pathology, *Chest* 134 (2008) 1183–1191.
- [9] R.A. Hartley, B.L. Barker, C. Newby, M. Pakkal, S. Baldi, R. Kajekar, et al., Relationship between lung function and quantitative computed tomographic parameters of airway remodeling, air trapping, and emphysema in patients with asthma and chronic obstructive pulmonary disease: a single-center study, *J. Allergy Clin. Immunol.* 137 (5) (2016) 1413–1422.
- [10] J.G. Krings, C.W. Goss, D. Lew, M. Samant, M.C. McGregor, J. Boomer, et al., Quantitative CT metrics are associated with longitudinal lung function decline and future asthma exacerbations: results from SARP-3, *J. Allergy Clin. Immunol.* 148 (3) (2021) 752–762.
- [11] R.L. Eddy, S. Svenningsen, M. Kirby, D. Knipping, D.G. McCormack, C. Liciskai, et al., Is computed tomography airway count related to asthma severity and airway structure and function? *Am. J. Respir. Crit. Care Med.* 15 (8) (2020) 923–933, 201.
- [12] S. Bodduluri, A. Kizhakke Puliyakote, A. Nakhmani, J.P. Charbonnier, J. M. Reinhardt, S.P. Bhatt, Computed tomography-based airway surface area-to-volume ratio for phenotyping airway remodeling in chronic obstructive pulmonary disease, *Am. J. Respir. Crit. Care Med.* 203 (2) (2021) 185–191.
- [13] E.M. Dunican, B.M. Elicker, D.S. Gierada, S.K. Nagle, M.L. Schiebler, J.D. Newell, et al., Mucus plugs in patients with asthma linked to eosinophilia and airflow obstruction, *J. Clin. Invest.* 128 (3) (2018) 997–1009.
- [14] G. David, Eleanor M. Dunican Mummy, Katherine J. Carey, et al., Fain mucus plugs in asthma at CT associated with regional ventilation defects at 3He MRI, *Radiology* 1 (2022) 184–190.
- [15] D.M. Hansell, A.A. Bankier, H. MacMahon, et al., Fleischner Society: glossary of terms for thoracic imaging, *Radiology* 246 (2008) 697–722.
- [16] I. Coman, B. Pola-Bibian, P. Barranco, G. Vila-Nadal, J. Dominguez-Ortega, D. Romero, et al., Bronchiectasis in severe asthma: clinical features and outcomes, *Ann. Allergy Asthma Immunol.* 120 (4) (2018) 409–413.
- [17] J. Tominaga, A.A. Bankier, K.S. Lee, A.N. Leung, M. Remy-Jardin, M. Akira, et al., Inter-observer agreement in identifying traction bronchiectasis on computed tomography: its improvement with the use of the additional criteria for chronic fibrosing interstitial pneumonia, *Jpn. J. Radiol.* 37 (2019) 773–780.
- [18] W. Kuo, M. de Bruijne, J. Petersen, K. Nasserinejad, H. Ozturk, Y. Chen, et al., Diagnosis of bronchiectasis and airway wall thickening in children with cystic fibrosis: objective airway-artery quantification, *Eur. Radiol.* 27 (11) (2017) 4680–4689.
- [19] Q. Lv, L. Gallardo Estrella, R. Latisenko, E.-R. Andrinopoulou, D.A. Lynch, H.A.W. M. Tiddens, et al., Airway-artery ratios of central and peripheral airways quantified on CT as independent predictors of airflow obstruction in COPD, *Am. J. Respir. Crit. Care Med.* 203 (2021) A4573.
- [20] V. Ranga, J. Kleinerman, Structure and function of small airways in health and disease, *Arch. Pathol. Lab Med.* 102 (12) (1978) 609–617.
- [21] E. van der Wiel, N.H. ten Hacken, D.S. Postma, M. van den Berge, Small-airways dysfunction associates with respiratory symptoms and clinical features of asthma: a systematic review, *J. Allergy Clin. Immunol.* 131 (3) (2013) 646–657.
- [22] J.H. Austin, N.L. Müller, P.J. Friedman, D.M. Hansell, D.P. Naidich, M. Remy-Jardin, et al., Glossary of terms for CT of the lungs: recommendations of the nomenclature committee of the fleischner society, *Radiology* 200 (2) (1996) 327–331.
- [23] A. Busacker, J.D. Newell, T. Keefe, E.A. Hoffman, J.C. Granroth, M. Castro, et al., A multivariate analysis of risk factors for the air-trapping asthmatic phenotype as measured by quantitative CT analysis, *Chest* 135 (1) (2019) 48–56.
- [24] S. Gupta, R. Hartley, U.T. Khan, A. Singapuri, B. Hargadon, W. Monteiro, et al., Quantitative computed tomography-derived clusters: redefining airway remodeling in asthmatic patients, *J. Allergy Clin. Immunol.* 133 (3) (2014) 729–738.
- [25] J.G. Krings, C.W. Goss, D. Lew, M. Samant, M.C. McGregor, J. Boomer, et al., National Heart, Lung, and Blood Institute's Severe Asthma Research Program Investigators. Quantitative CT metrics are associated with longitudinal lung function decline and future asthma exacerbations: results from SARP-3, *J. Allergy Clin. Immunol.* 148 (3) (2021) 752–762.
- [26] C.J. Galbán, M.K. Han, J.L. Boes, K.A. Chughtai, C.R. Meyer, T.D. Johnson, et al., Computed tomography-based biomarker provides unique signature for diagnosis of COPD phenotypes and disease progression, *Nat. Med.* 18 (11) (2012) 1711–1715.
- [27] E. Pompe, C.J. Galbán, B.D. Ross, L. Koenderman, N.H. Ten Hacken, D.S. Postma, et al., Parametric response mapping on chest computed tomography associates with clinical and functional parameters in chronic obstructive pulmonary disease, *Respir. Med.* 123 (2017) 48–55.
- [28] A.J. Bell, B.H. Foy, M. Richardson, A. Singapuri, E. Mirkes, M. van den Berge, et al., Functional CT imaging for identification of the spatial determinants of small-airways disease in adults with asthma, *J. Allergy Clin. Immunol.* 144 (1) (2019) 83–93.
- [29] M. Kraft, M. Richardson, B. Hallmark, D. Billheimer, M. Van den Berge, L. M. Fabbri, et al., The role of small airway dysfunction in asthma control and exacerbations: a longitudinal, observational analysis using data from the ATLANTIS study, *Lancet Respir. Med.* 10 (7) (2022) 661–668.
- [30] D.P. Mendoza, P. Kohli, J.W. Nance, R. Singh, J. Cho, J. Griffith, et al., Lung parenchymal and airway changes on CT imaging following allergen challenge and bronchoalveolar lavage in atopic and asthmatic subjects, *Ann. Transl. Med.* 8 (14) (2020) 862.
- [31] D.J. Roach, K. Ruangnapa, R.J. Fleck, M.S. Rattan, Y. Zhang, M. Hossain, et al., Structural lung abnormalities on computed tomography correlate with asthma inflammation in bronchoscopic alveolar lavage fluid, *J. Asthma* 57 (2020) 968–979.
- [32] N. Lessmann, C.I. Sánchez, L. Beenen, L.H. Boulogne, M. Brink, E. Calli, et al., Automated assessment of COVID-19 reporting and data system and chest CT severity scores in patients suspected of having COVID-19 using artificial intelligence, *Radiology* 298 (1) (2021) E18–E28.
- [33] R.S. Estepar, G.L. Kinney, J.L. Black-Shinn, R.P. Bowler, G.L. Kindlmann, J.C. Ross, et al., Study CopdGene, Computed tomographic measures of pulmonary vascular morphology in smokers and their clinical implications, *Am. J. Respir. Crit. Care Med.* 188 (2013) 231–239.
- [34] J.P. Charbonnier, M. Brink, F. Ciompi, E.T. Scholten, C.M. Schaefer-Prokop, E. M. van Rikxoort, Automatic pulmonary artery-vein separation and classification in computed tomography using tree partitioning and peripheral vessel matching, *IEEE Trans. Med. Imag.* 35 (3) (2016) 882–892.
- [35] P. Nardelli, D. Jimenez-Carretero, D. Bermejo-Pelaez, G.R. Washko, F.N. Rahaghi, M.J. Ledesma-Carbayo, et al., Pulmonary artery-vein classification in CT images using deep learning, *IEEE Trans. Med. Imag.* 37 (11) (2018) 2428–2440.
- [36] D. Jimenez-Carretero, D. Bermejo-Pelaez, P. Nardelli, P. Fraga, E. Fraile, R. San José Estepar, M.J. Ledesma-Carbayo, A graph-cut approach for pulmonary artery-vein segmentation in noncontrast CT images, *Med. Image Anal.* 52 (2019) 144–159.
- [37] S.I. Said, S.A. Hamidi, L. Gonzalez Bosc, Asthma and pulmonary arterial hypertension: do they share a key mechanism of pathogenesis? *Eur. Respir. J.* 35 (4) (2010) 730–734.
- [38] S.B. Fain, G. Gonzalez-Fernandez, E.T. Peterson, M.D. Evans, R.L. Sorkness, N. N. Jarjour, et al., Evaluation of structure-function relationships in asthma using multidetector CT and hyperpolarized He-3 MRI, *Acad Radiol.* Jun 15 (6) (2008) 753–762.
- [39] J.W. Jung, J.W. Kwon, T.W. Kim, S.H. Lee, K.M. Kim, H.R. Kang, et al., New insight into the assessment of asthma using xenon ventilation computed tomography, *Ann. Allergy Asthma Immunol.* 111 (2) (2013) 90–95.
- [40] G.T. Mussell, H. Marshall, L.J. Smith, A.M. Biancardi, P.J. Hughes, D.J. Capener, et al., Xenon ventilation MRI in difficult asthma: initial experience in a clinical setting, *ERJ open research* 1 (3) (2021) 7.
- [41] H.W. Park, J.W. Jung, K.M. Kim, T.W. Kim, S.H. Lee, C.H. Lee, et al., Xenon ventilation computed tomography and the management of asthma in the elderly, *Respirology* 19 (3) (2014) 389–395.
- [42] T.A. Altes, J.P. Mugler, K. Ruppert, N.J. Tustison, J. Gersbach, S. Szentpetery, et al., Clinical correlates of lung ventilation defects in asthmatic children, *J. Allergy Clin. Immunol.* 137 (3) (2016) 789, 96.e7.
- [43] G.T. Mussell, H. Marshall, L.J. Smith, A.M. Biancardi, P.J.C. Hughes, D.J. Capener, et al., Xenon ventilation MRI in difficult asthma: initial experience in a clinical setting, *ERJ Open Res* 7 (2021) 785–2020.
- [44] R.P. Thomen, A. Sheshadri, J. Quirk, J. Kozlowski, H.D. Ellison, R.D. Szczesniak, et al., Regional ventilation changes in severe asthma after bronchial thermoplasty with 3He MR imaging and CT, *Radiology* 274 (2015) 250–259.

- [45] C.S. Hall, J.D. Quirk, C.W. Goss, D. Lew, J. Kozlowski, R.P. Thomen, et al., Single-session bronchial thermoplasty guided by 129Xe magnetic resonance imaging. A pilot randomized controlled clinical trial, *Am J Respir Crit Care Med* [Internet] 202 (4) (2020) 524–534.
- [46] Rachel L. Eddy, Sarah Svenningsen, Christopher Licskai, David G. McCormack, Grace Parraga hyperpolarized helium 3 MRI in mild-to-moderate asthma: prediction of postbronchodilator reversibility, *Radiology* 293 (1) (2019) 212–220.
- [47] D.P.I. Capaldi, R.L. Eddy, S. Svenningsen, F. Guo, J.S.H. Baxter, A.J. McLeod, P. Nair, D.G. McCormack, G. Parraga, Canadian Respiratory Research Network, Free-breathing pulmonary MR imaging to quantify regional ventilation, *Radiology* 287 (2) (2018) 693–704.
- [48] H. Marshall, A. Voskrebenev, L.J. Smith, A.M. Biancardi, A.L. Kern, G.J. Collier, et al., 129Xe and free-breathing 1H ventilation MRI in patients with cystic fibrosis: a dual-center study, *J. Magn. Reson. Imag.* (2022), <https://doi.org/10.1002/jmri.28470>.
- [49] L. Behrendt, L.J. Smith, A. Voskrebenev, F. Klimes, T.F. Kaireit, G.H. Pohler, et al., A dual center and dual vendor comparison study of automated perfusion-weighted phase-resolved functional lung magnetic resonance imaging with dynamic contrast-enhanced magnetic resonance imaging in patients with cystic fibrosis, *Pulm. Circ.* 12 (2) (2022), e12054.
- [50] N.S. Higano, D.R. Spielberg, R.J. Fleck, A.H. Schapiro, L.L. Walkup, A.D. Hahn, et al., Neonatal pulmonary magnetic resonance imaging of bronchopulmonary dysplasia predicts short-term clinical outcomes, *Am. J. Respir. Crit. Care Med.* 198 (10) (2018) 1302–1311.
- [51] K. Bae, K.N. Jeon, M.J. Hwang, J.S. Lee, J.Y. Ha, K.H. Ryu, et al., Comparison of lung imaging using three-dimensional ultrashort echo time and zero echo time sequences: preliminary study, *Eur. Radiol.* 29 (5) (2019) 2253–2262.
- [52] P.J. Niedbalski, C.S. Hall, M. Castro, R.L. Eddy, J.H. Rayment, S. Svenningsen, et al., Protocols for multi-site trials using hyperpolarized 129Xe MRI for imaging of ventilation, alveolar-airspace size, and gas exchange: a position paper from the 129Xe MRI clinical trials consortium, *Magn. Reson. Med.* 86 (6) (2021) 2966–2986.
- [53] J. Petersen, M.M. Wille, L.L. Rakèt, A. Peragen, J.H. Pedersen, M. Nielsen, et al., Effect of inspiration on airway dimensions measured in maximal inspiration CT images of subjects without airflow limitation, *Eur. Radiol.* 24 (9) (2014) 2319–2325.
- [54] M.E. Bakker, J. Stolk, J.H. Reiber, B.C. Stoel, Influence of inspiration level on bronchial lumen measurements with computed tomography, *Respir. Med.* 106 (5) (2012) 677–686.
- [55] E. Pompe, E.M. van Rikxoort, O.M. Mets, J.P. Charbonnier, J.M. Kuhnigk, H.J. de Koning, et al., Follow-up of CT-derived airway wall thickness: correcting for changes in inspiration level improves reliability, *Eur. J. Radiol.* 85 (11) (2016) 2008–2013.
- [56] E. Salamon, S. Lever, W. Kuo, P. Ciet, H.A. Tiddens, Spirometer guided chest imaging in children: it is worth the effort, *Pediatr. Pulmonol.* 52 (2017) 48–56.
- [57] K.P. Exarchos, M. Beltsiou, C.-A. Votti, K. Kostikas, Artificial intelligence techniques in asthma: a systematic review and critical appraisal of the existing literature, *Eur. Respir. J.* 56 (2020), 2000521.
- [58] F. Jiang, Y. Jiang, H. Zhi, Y. Dong, H. Li, S. Ma, et al., Artificial intelligence in healthcare: past, present and future, *Stroke Vasc Neurol* 2 (2017) 230–243.
- [59] R. Chan, B.J. Lipworth, Impact of biologic therapy on the small airways asthma phenotype, *Lung* 200 (6) (2022) 691–696.
- [60] M.J. McIntosh, H.K. Koener, R.L. Eddy, S. Jeimy, C. Licskai, C.A. Mackenzie, et al., Asthma control, airway mucus, and 129Xe MRI ventilation after a single benralizumab dose, *Chest* 162 (3) (2022) 520–533.
- [61] A. Menzies-Gow, M. Bafadhel, W.W. Busse, T.B. Casale, J.W.H. Kocks, I.D. Pavord, et al., An expert consensus framework for asthma remission as a treatment goal, *J. Allergy Clin. Immunol.* 145 (3) (2020) 757–765.